

CANINE ALOPECIA

Congenital?

Acquired?

Hairfollicle A/
dyspalsia

Yes

Yes

Self-
inflicted ?

No

Pruritus

Focal/multifocal
alopecia
Inflammatory ?

Symmetric/diffuse
alopecia
Non
inflammatory ?

Infections

Cytology,
skin scrapings,
trichoscopy,

CBC, chemistry profile,
urology, diagnostic imaging,
endocrine evaluation and/or
skin biopsy

Endocrinopathies

-
>>biopsy

- Mural and interface
follikulitis without infectious
agents
- bulbitis

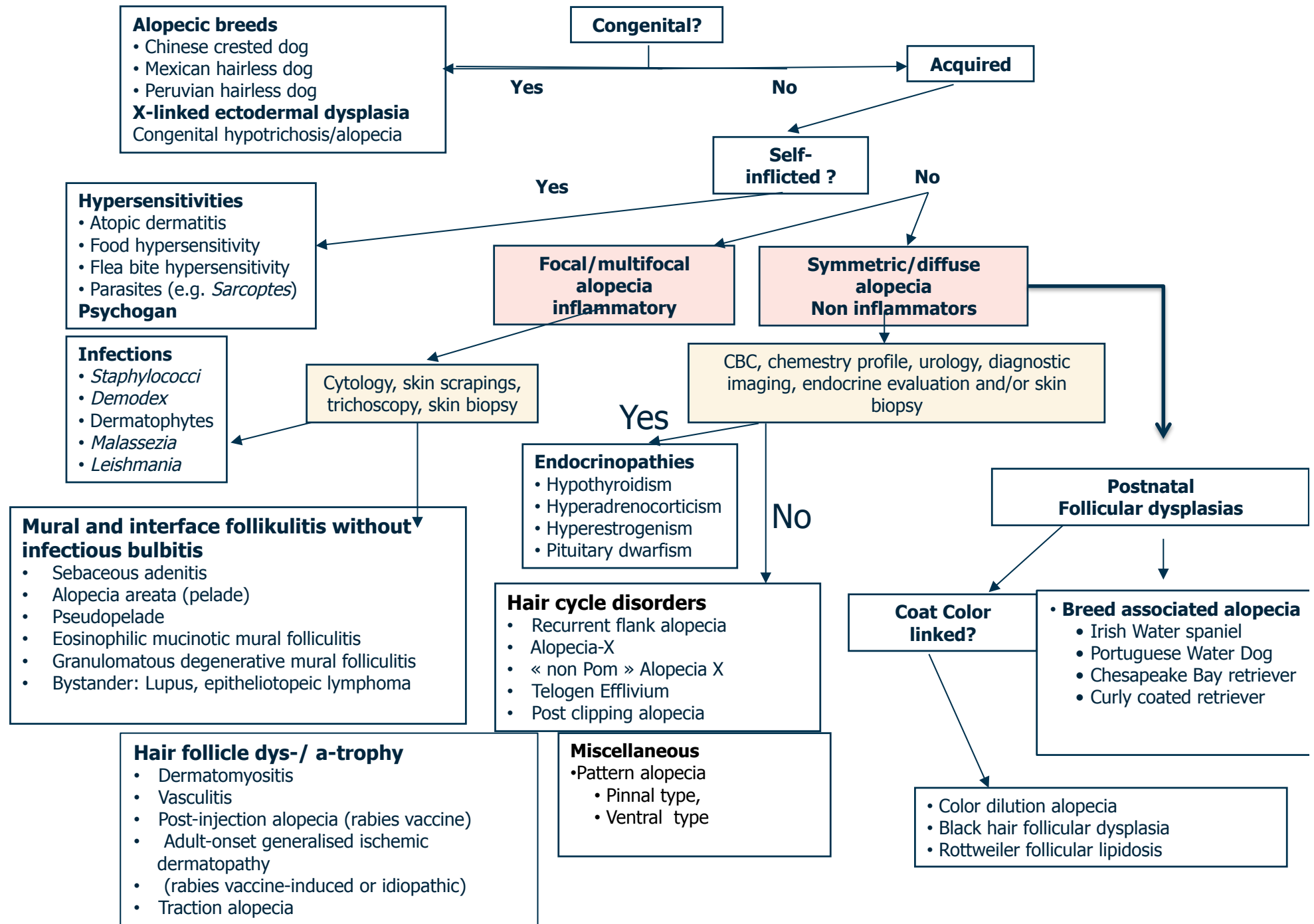
Hair cycle disorders
Miscellaneous

Postnatal
Follicular dysplasias

Hair follicle dys-/ a-trophy

Coat color-
linked

Breed associated



Alopecic breeds

- Chinese crested dog
- Mexican hairless dog
- Peruvian hairless dog

X-linked ectodermal dysplasia
Congenital hypotrichosis/alopecia

Congenital?

Acquired

Hypersensitivities

- Atopic dermatitis
- Food hypersensitivity
- Flea bite hypersensitivity
- Parasites (e.g. *Sarcoptes*)

Psychogen

Self-inflicted ?

Focal/multifocal alopecia inflammatory

Symmetric/diffuse alopecia Non inflammators

Infections

- *Staphylococci*
- *Demodex*
- Dermatophytes
- *Malassezia*
- *Leishmania*

Cytology, skin scrapings, trichoscopy, skin biopsy

CBC, chemistry profile, urology, diagnostic imaging, endocrine evaluation and/or skin biopsy

Mural and interface folliculitis without infectious bulbitis

- Sebaceous adenitis
- Alopecia areata (pelade)
- Pseudopelade
- Eosinophilic mucinotic mural folliculitis
- Granulomatous degenerative mural folliculitis
- Bystander: Lupus, epitheliotopeic lymphoma

Endocrinopathies

- Hypothyroidism
- Hyperadrenocorticism
- Hyperestrogenism
- Pituitary dwarfism

Hair cycle disorders

- Recurrent flank alopecia
- Alopecia-X
- « non Pom » Alopecia X
- Telogen Effluvium
- Post clipping alopecia

Postnatal Follicular dysplasias

Coat Color linked?

Breed associated alopecia

- Irish Water spaniel
- Portuguese Water Dog
- Chesapeake Bay retriever
- Curly coated retriever

Hair follicle dys-/ a-trophy

- Dermatomyositis
- Vasculitis
- Post-injection alopecia (rabies vaccine)
- Adult-onset generalised ischemic dermatopathy
- (rabies vaccine-induced or idiopathic)
- Traction alopecia

Miscellaneous

- Pattern alopecia
- Pinnal type,
- Ventral type

- Color dilution alopecia
- Black hair follicular dysplasia
- Rottweiler follicular lipodosis

FELINE ALOPECIA

